Case Report

"William Tell" Injury: MDCT of an Arrow Through the Head

Katrijn de Jongh[1], Dinska Dohmen[2], Rodrigo Salgado[1], Özkan Özsarlak[1], Johan W. M. Van Goethem[1], Luc Beaucourt[2], Philippe G. Jorens[3], Tony W. Van Havenbergh[4], Arthur M. De Schepper[1], Paul M. Parizel[1]

American Journal of Roentgenology 2004.182:1551-1553.

Crossbow injuries to the head are extremely rare [1–8]. Most documented cases are suicide attempts, often with fatal outcomes. We describe a 22-year-old man with a self-inflicted crossbow head injury who survived. The position of the arrow and the associated bone and soft-tissue abnormalities are shown using a 16-MDCT scanner and postprocessing reformations. We also present an overview of all reported cases of crossbow injuries to the brain.

Case Report

A 22-year-old man attempted to commit suicide by shooting an aluminum crossbow arrow through his mouth. The arrow entered the skull through the oral cavity and exited the skull near the vertex (Fig. 1A). When the mobile emergency medical team arrived, the patient was fully conscious but was blind in his right eye and complained of a left-sided hemiparesis. The patient was intubated and ventilated, and his head was immobilized. Initial treatment consisted of IV administration of corticosteroids and analgetics. Sixteen-MDCT scans were obtained when the patient arrived at the hospital (Figs. 1B and 1D).

Axial CT scans documented the trajectory of the arrow. It penetrated the right ethmoidal and sphenoid sinuses, passed through the right optic canal, entered the cranial cavity immediately lateral to the anterior cerebral arteries, continued vertically through the right periventricular area and right frontal deep white matter, and finally exited through the frontal skull near the vertex. The right-sided blindness was presumably caused by injury to the optic nerve, and the left-sided hemiparesis was caused by right hemispheric parenchymal injury. Multiplanar CT reformatting was performed in the sagittal plane to document the entire trajectory of the hollow arrow shaft. The relationship of the arrow to the skull base and cranial vault was documented using a volume-rendering technique with virtual removal of the occipital bone.

The patient immediately underwent surgery. The arrowhead was removed, and the shaft of the missile was extracted through the mouth. An external ventricular drain was inserted.

Postoperatively, the patient was transferred to the neurosurgical ICU. He developed sepsis and was treated with broad-spectrum antibiotics for 3 weeks. Intracranial hypertension was not observed. On postoperative day 15, the patient underwent a second surgical intervention because of a cerebrospinal fluid leak through the mouth—the arrow tract was partially filled with autologous fat from the thigh. A follow-up CT scan showed no signs of cerebritis. CT angiography revealed no evidence of a post-traumatic aneurysm. The patient recovered amazingly well and was discharged from the neurosurgical ICU tp the ward on day 20 with a right-sided hemianopsia and slight paresis of the left leg. On day 31, the patient was discharged from the hospital in stable condition.

Discussion

Crossbow injuries to the head are rare, with only a handful of cases reported in the literature [1–8] (Table 1). Most documented cases were self-inflicted injuries that often had fatal outcomes. Compared with firearm projectiles, aluminum crossbow arrows have a relatively low velocity (as fast as 58 m/sec), but their sharpness and kinetic energy are sufficient to cause penetrating skull injuries [2]. A study of the ballistics of experimental arrow wounds by Karger et al. [3] showed that the penetration mechanism of an arrow is distinct from that of a bullet, because of the extremely sharp cutting edge of the arrowhead. Because of the sharp force applied by arrows, injury is limited to the tissues that are directly incised by the blade of the arrowhead [3]. From both a patient treatment and a forensic point of view, the arrow should be left in situ and stabilized to limit motion in transport until the patient reaches surgery. The shaft of the arrow in situ appears to exert pressure on the wound, thus functioning as an incomplete tamponade. Because the tip of the sports arrow is

Received June 16, 2003; accepted after revision August 18, 2003.

[1]Department of Radiology, University Hospital Antwerp, Wilrijkstraat 10, Edegem 2650, Belgium. Address correspondence to K. de Jongh (katrijn.de.jongh@uza.be).

[2]Department of Emergency Medicine, University Hospital Antwerp, Edegem 2650, Belgium.

[3]Department of Intensive Care Medicine, University Hospital Antwerp, Edegem 2650, Belgium.

[4]Department of Neurosurgery, University Hospital Antwerp, Edegem 2650, Belgium.

AJR 2004;182:1551–1553 0361–803X/04/1826–1551 © American Roentgen Ray Society

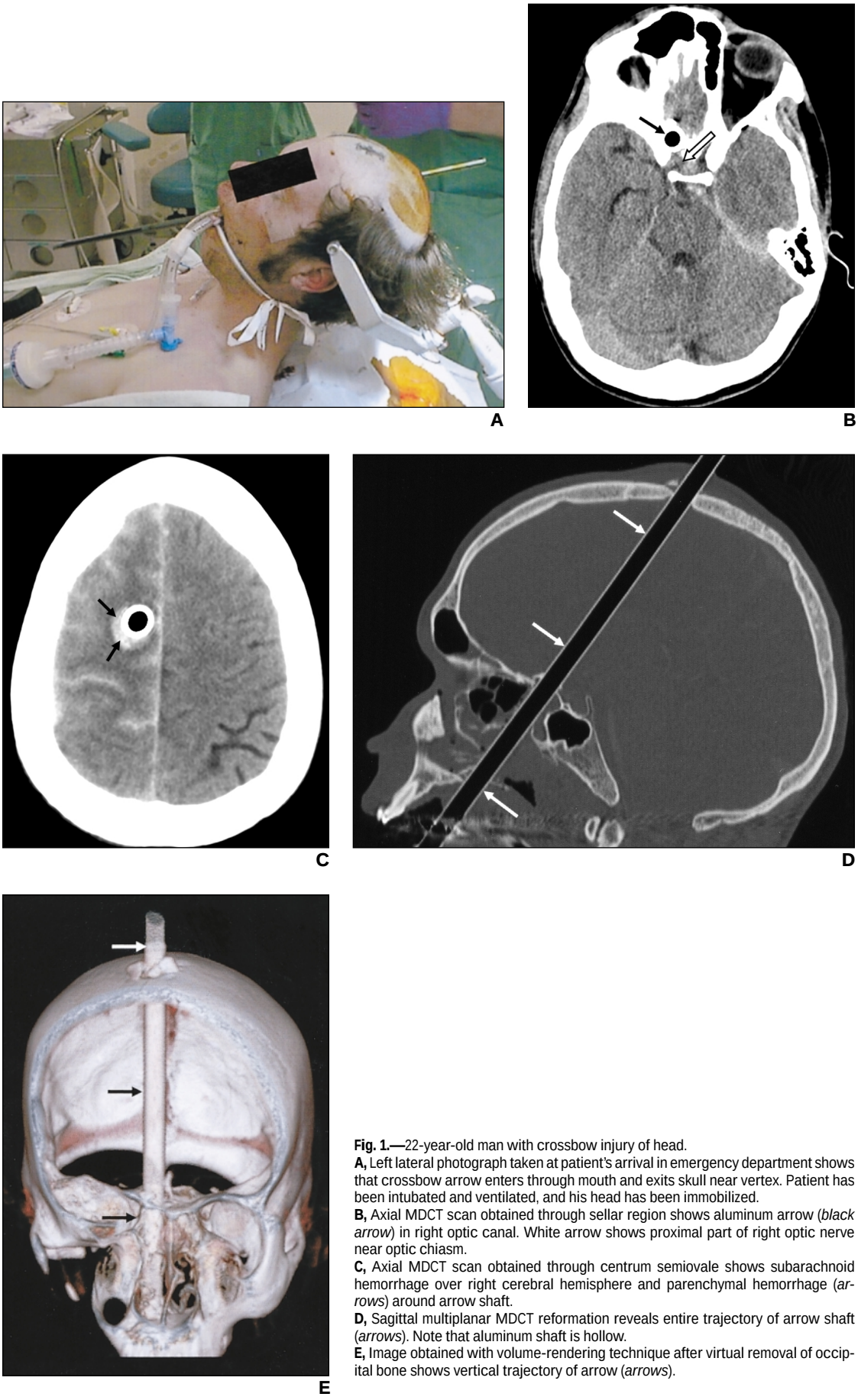

Fig. 1.—22-year-old man with crossbow injury of head.
A, Left lateral photograph taken at patient's arrival in emergency department shows that crossbow arrow enters through mouth and exits skull near vertex. Patient has been intubated and ventilated, and his head has been immobilized.
B, Axial MDCT scan obtained through sellar region shows aluminum arrow (*black arrow*) in right optic canal. White arrow shows proximal part of right optic nerve near optic chiasm.
C, Axial MDCT scan obtained through centrum semiovale shows subarachnoid hemorrhage over right cerebral hemisphere and parenchymal hemorrhage (*arrows*) around arrow shaft.
D, Sagittal multiplanar MDCT reformation reveals entire trajectory of arrow shaft (*arrows*). Note that aluminum shaft is hollow.
E, Image obtained with volume-rendering technique after virtual removal of occipital bone shows vertical trajectory of arrow (*arrows*).

American Journal of Roentgenology 2004.182:1551-1553.

American Journal of Roentgenology 2004.182:1551-1553.

TABLE 1 Reported Cases of Brain Injury Caused by Crossbow Arrows

Source	Patient Age (yr)	Cause of Injury	Entry Point	Symptoms	Trajectory of Arrow	Surgery	Complications	Outcome
Salam et al., 1990 [7]	24	Unintentional	Right temporal lobe	GCS score, 3/15	Through right temporal lobe between tectum and tegmentum	No	None	Almost full recovery
Downs et al., 1994 [4]	—	Suicide	Right upper eyelid	Pulling at arrow	Through right frontal lobe, lateral ventricle, and right occipital lobe	No	NA	Death in 2 hr
Opeskin and Burke, 1994 [5]	44	Suicide	1. Between left eye and nose 2. Through lower lip and upper palate	NA	1. Broken arrow in base of left frontal lobe 2. Through base of right temporal lobe	No	NA	Death
Byard et al., 1999 [2]	18	Suicide	Between right ear and eye	GCS score, 3/15	Through right middle cranial fossa and diencephalon into left parietal lobe	No	NA	Death
Byard et al.,1999 [2]	27	Suicide	Chin	NA	Through optic chiasm with damage to basal ganglia	No	NA	Death
Franklin and Lukan, 2002 [1]	15	Attempted suicide	Posterior oral pharynx	GCS score, 7/15	Posterior to sella turcica, through occipital lobe	Arrow removed	None	Answers to simple questions, decreased motor activity on the right, simple one-step commands on the left
Joly et al., 2002 [8]	42	Attempted suicide	Chin	GCS score, 15/15	Through ethmoid bone between the frontal lobes	Arrow removed through frontal craniotomy	Streptococcal meningitis	Full recovery
de Jongh et al., 2004	22	Attempted suicide	Upper palate	GCS score, 15/15; right hemianopsiaand left hemiparesis	Through ethmoidal sinus and right optic nerve canal	Arrow removed through ethmoidal sinus	Sepsis	Hemianopsia and mild hemiparesis

Note.—In all cases reported to date, the patients have been male. Dash indicates missing data. GCS = Glasgow Coma Scale, NA = not applicable.

the same diameter as the shaft, these lesions can be survivable. In our patient, the trajectory of the crossbow arrow was slightly anterior to the cavernous sinus and lateral to the anterior cerebral arteries, which prevented fatal vascular injury. However, the right optic nerve was damaged and caused a permanent right-sided loss of vision.

MDCT is the technology of choice for acquiring CT data in a complex neurotrauma case. The increased spatial resolution allows for high-quality 3D postprocessing [9]. In this case, volume-rendered and multiplanar reformatted images provided clinically relevant information for the management of this complex neurotrauma. The reformatted images clearly depict the anatomic relationships and are much easier to interpret than hundreds of thin axial images, especially for nonradiologists. Postprocessing techniques also allow the radiologist and treating neurosurgeon to explore the findings together interactively on a workstation and improve their preoperative evaluation of the patient.

In conclusion, crossbow injuries to the head are rare and pose a medical and surgical challenge. This case illustrates the potential of 3D images as aids in treating complex penetrating neurotrauma. With postprocessing, the total acquired scanning volume is represented on a few significant views with a high degree of accuracy, thereby accentuating the diagnostically relevant details and facilitating the planning of further therapy.

References

1. Franklin GA, Lukan JK. Self-inflicted crossbow injury to the head. *J Trauma* 2002;52:1009
2. Byard RW, Koszyca B, James R. Crossbow suicide: mechanisms of injury and neuropathologic findings. *Am J Forensic Med Pathol* 1999;20:347–353
3. Karger B, Sudhues H, Beat P, Kneubuehl MS, Brinkmann B. Experimental arrow wounds; ballistics and traumatology. *J Trauma* 1998;45:495–501
4. Downs JC, Nichols CA, Scala-Barnett D, Lifschultz BD. Handling and interpretation of crossbow injuries. *J Forensic Sci* 1994;39:428–445
5. Opeskin K, Burke M. Suicide using multiple crossbow arrows. *Am J Forensic Med Pathol* 1994;15:14–17
6. Rogers C, Dowell S, Choi JH, Sathyavagiswaran I. Crossbow injuries. *J Forensic Sci* 1990;35:886–890
7. Salam A, Eyres KS, Magides AD, Cleary J. Penetrating brain stem injury from crossbow bolt: a case report and review of the literature. *Arch Emerg Med* 1990;7:224–227
8. Joly LM, Oswald AM, Disdet M, Ragueneau JL. Difficult endotracheal intubation as a result of penetrating cranio-facial injury by an arrow. *Anesth Analg* 2002;94:231–232
9. Pretorius ES, Fishman EK. Volume-rendered three-dimensional spiral CT: musculoskeletal applications. *RadioGraphics* 1999;19:1143–1160