



Arrow Injuries – in Current Scenarios

Authors

Rinku Yadav¹, Shailendra Singh², R.K. Mathur³, Sonia Moses⁴, Ankur Maheshwari⁵

¹General Practitioner, Former Post Graduate Resident in Surgery Department M.G.M. Medical College & M.Y. Hospital Indore M.P.

²Senior Resident, S.S. Medical College & SG.M.H & G.M. Hospital Rewa M.P, Former Post Graduate Resident in Surgery Department M.G.M. Medical College & M.Y. Hospital Indore M.P.

³Professor & Head Surgery Department M.G.M. Medical College & M.Y. Hospital Indore M.P.

⁴Associate Professor Surgery Department M.G.M. Medical College & M.Y. Hospital Indore M.P.

⁵Assistant Professor Surgery Department M.G.M. Medical College & M.Y. Hospital Indore M.P.

Corresponding Author

Dr Shailendra Singh

Senior Resident Surgery Department, S.S. Medical College & S.G.M.H.& GM. Hospital Rewa M.P

Email: shailussmc@gmail.com

Abstract

Background: Penetrating injuries by traditional weapons are rare entity in the modern era of sophisticated weapons. Arrow are low velocity projectile weapon and from a close proximity they can cause penetrating trauma similar to a low powered handgun. Incident and their Management of the cases were discussed.

Aims and Objectives: To collect the epidemiological data of arrow injuries cases and various mode of presentations & their management.

Materials and Methods: The study was designed to collect data of patients presenting with arrow injuries which were managed in M. Y. Hospital since 2010 to 2015 (6 years). Data was collected in retrospective manner from 2010 to 2013 by medical records and In Prospective manner from September 2013 to October 2015. Follow up of these cases was done for immediate post-operative period of one month. The injuries were classified according to the organ system concerned and management accordingly.

Result: A total 70 cases of Arrow injury were included in the study. There were sixty nine males (98.57%) and one female (1.428%). The peak age of incidence was 35yrs. Thirty seven patients (52.86%) were presented with arrow in-situ and thirty three patients (47.14%) presented after extraction of arrow. Out of seventy patients, twenty seven(38.57%) were chest injuries, twenty four (34.29%) were abdominal injuries, three(4.29%) of thoraco-abdominal and remaining sixteen(22.86%) patients were head, neck and limbs injuries cases. All patients were managed surgically according to injuries.

Conclusion: Arrow injuries still exist in developing societies. Arrow injuries are the result of tribal conflicts and pose considerable challenges in their management; however with adequate resuscitation and adherence to the proposed principles for extraction the outcome is good.

Keywords: Arrow Injuries, Extraction, projectile, penetrating, chest injury, abdominal injury.

Introduction

Arrow warfare and its resultant injuries is a rarity today due to availability of a wide range of modern firearm devices. Arrows are used for hunting and tribal wars in developing country. Arrow injuries are a special type of penetrating injuries and its management is still relevant in this century, more so because of the preponderance of tribal population in India. Tribal belts of malwa region of Madhya Pradesh where arrow injuries commonly encounter are jhabua, alirajpur, khargonand manawar. Arrow injuries incidents increase during tribal festival like bhagoria Diwali. Bhagoria festival is celebrated by the tribal people of Madhya Pradesh in India^[1] (originally known as 'Malwa'). Also known as Bhagoria Haat Festival, during this festival, young boys and girls are allowed to elope after choosing their partners. The Bhagoria Haat Festival belongs to the local tribes called Bhils and Bhilalas.

Bhagoria Haat Festival is organized in the district of West Nimar (Khargon) and Jhabua. The haat is organized in the form of a 'swayamvar' or a marriage market where young girls and boys are allowed to choose their partners. Bhagoria Haat Festival has an agricultural significance attached to it. It coincides with the end of harvesting. So some people also celebrate it to mark the completion of harvesting.

But the important attraction of Bhagoria Haat Festival of Madhya Pradesh is the running away of young boys and girls with their partner who are later accepted as husband and wife by the society. During the Bhagoria Haat Festival in Madhya Pradesh, the boys put red powder on the face of the girl to whom he wants to get married, if the girl too wishes to marry the same boy, she has to put the same red powder on the boy's face after which both of them run away from that place. But if the girl does not agree in the first chance, the boy can go behind her to persuade her and may win her heart.

Bhagoria Haat Festival at Madhya Pradesh is celebrated in the month of March before the Holi festival.

The cause of these injuries was due to tribal wars or personal rivalry or thefts. The rate of haemorrhage from arrow injury are generally less than gunshot injury, unless vital structures such as the heart, great vessels or major vascular pedicles are injured which may lead to rapid blood loss. The arrowhead should not be disturbed prior to surgery and should be extracted after complete exploration of the track. Patients in whom an arrow has been extracted prior to admission are relatively easier to treat, while those with arrows in-situ require additional care and skill in removing the arrow. Heavy instrument such as Kocher's or Robert's forceps are useful and attempt to blind extraction is an invitation to disaster more so if major vessels have been involved. Rotation of the arrowhead during extraction is condemned because it can aggravate internal injury. If neurovascular injury is suspected proximal and distal emobilization and control is required after exploration. Impalement of arrow into vertebral bodies and retroperitoneal is common. While removing the arrows, utmost care necessary to prevent aggravation of internal injury as well as injury to operating surgeon by the sharp blades of the Arrow. Anterior intraperitoneal injuries mandate a laparotomy. For lateral wounds with arrow in-situ a transverse abdominal incision is preferable because the deeply lodged arrow tends to anchor the abdominal wall, prevents its retraction and gives inadequate exposure of the viscera.

Materials and Methods

This study was designed to collect data of patients presenting with arrow injuries which were managed in department of surgery MGM medical college & Maharaja Yashwantrao Hospital, a tertiary care centre in Central India from January 2010 to October 2015 (6 years). Data was collected retrospectively from 2010 to 2013. The audit was done by looking up old case records. Prospective data was analysed for all patients with arrow injuries from September 2013 to October 2015. Follow up of these cases was done for immediate post-operative period of one month. The injuries

were classified according to the organ system concerned and their management.

Results

A total of 70 patients presented in hospital with penetrating arrow injuries between January 2010 to October 2015(6years). There were 69 male (98.57%) and 1 female patients (1.428%). Usually the patients with penetrating injuries by arrows are haemodynamically stable unless the arrow has involved some major vessels as aorta or inferior vena cava or some very vascular organ as spleen or liver . All the patients were from the tribal belt. The mean age of the patients was 35 years, the youngest being 15 years old and eldest was 70 years of age. Out of 70 patients, 37 (52.86%) had arrow in-situ on presentation and 33(47.14%) had their arrow extracted mostly by themselves before presentation.

They were categorized into four groups for the analysis of data.

Group A Chest injuries seen in 27 patients (38.57%)

Group B Abdominal injuries seen in 24 patients (34.29%)

Group C Thoraco-abdominal injuries seen in 3 patients (4.29%)

Group D Injuries to head, neck and extremities seen in 16 patients (22.86%)

Group A: Majority of them had lung tears. No other mediastinal structures were involved. Out of 27 patients 4 were explored with a thoracotomy and 5 were ICD done under local anaesthesia, rest 18 patients were primary wound closed and debridement done. . Amongst the thoracic wounds a few may have respiratory distress due to gross haemopneumothorax. Lungs were the organs involved in 7 patients of the 7 explored. But no injuries to major vessels or heart was seen. This may be because patients with such grave injuries succumbed to their injuries before receiving medical help considering the distance these tribal have to travel to reach a hospital. Those patients with penetrating thoracic wounds, who were stable on presentation with no evidence of arrow

in-situ were managed conservatively with intercostal drainage. Indications for thoracotomy were as follows:-

1. Clinical and radiological evidence of arrow in-situ.
2. ICD drainage more than 1000ml of blood on insertion or constant bleeding at a rate of more than 100ml in 15 minutes.

Group B : Most of the wounds were over the anterior abdominal wall. A few (only 2) had bowels and 2 had omentum prolapsing through the wound. All patients underwent an exploratory laparotomy and the organs injured are as Stomach and Jejunum were the most commonly involved organ followed by colon liver and ileum. There were two instances of gallbladder injuries. Out of 24 patients, 8 were managed conservatively and 13 were Exploratory Laparotomy under general anaesthesia 3 were exploration of wound and removed arrows. All patients with penetrating arrow injury of abdominal wounds explored with a laparotomy. The whole trajectory of the arrow was traced. This had at times revealed injuries which were not obvious at once and were diagnosed only on complete exploration e.g. Duodenal or ureteral injuries

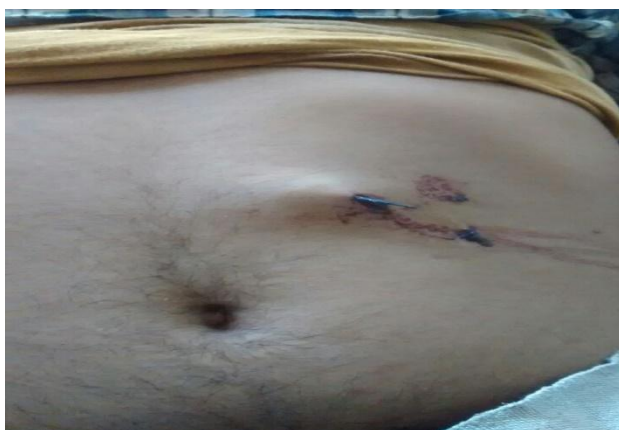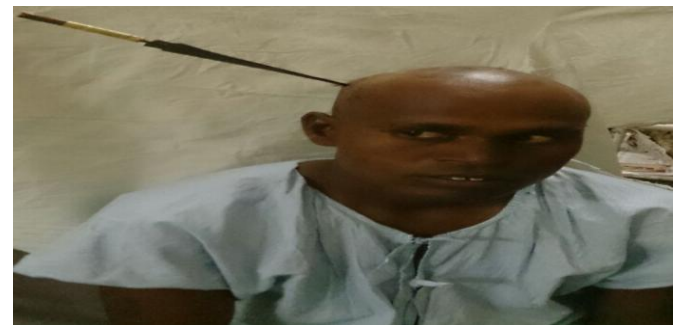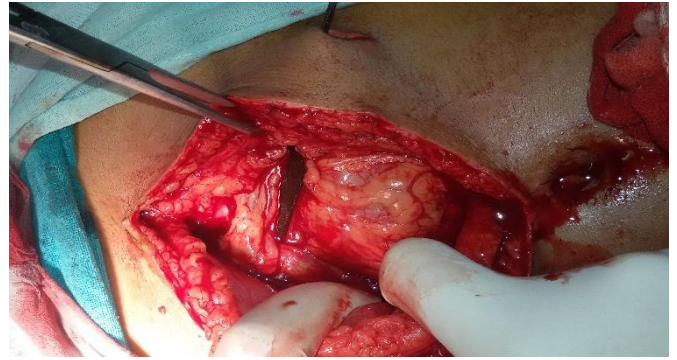
Group C: All the patients had arrow in-situ in this group. All the patients of combined thoraco-abdominal injuries were explored. All the patients had injuries to the lung and the arrow had penetrated the diaphragm to involve the abdomen. Liver and stomach were the most common abdominal organ involved.

Group D: Out of 16 patients, 07 had arrow in-situ. Most common involved head & neck region. Arrow injuries to the extremities also are explored unless it is a very superficial wound with no evidence of deep extension.

Impacted arrow in soft tissue was difficult to explore, arrow should left in-situ the wound for 7 to 10 days. When organization developed then remove the arrow.

Out of 70 patients 66 were discharged (94.28 %) and one had left against medical advice, 3 (4.2857%) were died . Factors leading to death in

these patients were sever haemorrhagic shock, septicaemia, pneumonia with respiratory failure, delay in receiving medical help and post-operative due to septicaemia resulting from pulmonary complications or faecal fistula. Few complications seen with arrow injuries. These were pulmonary complications like atelectasis /pneumonia, intestinal fistula due to leakage of anastomosis. Both of which may cause septicaemia. Few patients develop wound infection which is usually superficial. All of these may leads to increase the post-operative morbidity and prolong hospital stay. However the outcome is usually good and there were no chronic complications from arrow injuries as seen on follow-up of these patients. Total morbidity rate was 10 out of 70. Complications encountered were more or less similar.



Conclusion

Arrow injuries still exist in developing societies. Arrow injuries are the result of tribal conflicts and pose considerable challenges in their management. The management of arrow injuries should be along the lines of standard principles of trauma management. The arrow should not be disturbed. Simple investigations like x-ray and USG usually sufficient for workup and planning the management. On exploration, of utmost importance is not to disturb the arrow until the complete

References

1. Cina SJ, Radentz55, Smialek JE. Suicide using a compound bow and arrow Am J Forensic Med PathoI1998; 19(1):102-5.
2. Eriksson A, Gearen B, Ostrom M. Work place homicide by bow and arrow. J Forensic Sci 2000; 45(4):911-6.
3. Faber RG. Ureteric injury caused by penetrating arrow wound. J R Coil surg Edinb 1974; 19(4):241-3.
4. Fingleton U. Arrow wounds to the heart mediastinum. Br J Surg 1987; 74(2): 126-8.

5. Jacob OJ, Penetrating thoracoabdominal injuries with arrows: experience with 63 patients. Aust N Z J Surg 1995; 65:394-7.
6. Jacob Oj, Rosenfeld JV, Taylor RH , Watters DAK. Late complications of arrow and spear wounds to the head and neck. J Trauma 1999; 47(4):768-73.
7. Karger B, Sudhues H, Brinkmann B. Arrow wounds: major stimulus in the history of surgery. World J Surg 2001; 25(12): 1550-5.
8. Karger B, Sudhues H, Kneubuehl BP, Brinkmann B. Experimental arrow wounds: ballistics and traumatology. J Trauma 1998; 45(3):495-501.
9. Karlsson 1; Stahling S. Experimental blowgun injuries, ballistic aspects of modern blowguns. Forensic SciInt 2000; 112:59-64.
10. Neal G, Downing EF .Clostridial meningitis as a result of craniocerebral arrow injury. J Trauma 1996; 40(3):476-80.
11. Pandey S, Sinha SN, Jha B, etai. An unusual arrow injury. Intsurg 1972; 57(7):589.
12. Peloponissions N, Halkic N, Moeschler O, et al. Penetrating thoracic trauma in arrow injuries. Ann Thorac Surg 2001; 71:1019-21.
13. Ricci MR. The arrow –head which went through the brain. East Afr Med J 1999; 76(7):411-3.
14. Singh RJ, Singh NK. Arrow injury. J Indian Med Assoc 1985; 83(2):65-6.
15. VanGup G, Hutchison TJ, Alto WA. Arrow wound management in Papua New Guinea. J Trauma 1990; 30(2):183-8.
16. Paramhans D, Shukla S, Batra A, Mathew R. Successful removal of an implanted metallic arrowhead penetrating up to brainstem. J Emerg Trauma Shock 2010; 3: 303.
17. Katrijn dJ, Dinska D, Rodrigo S, Ozkan O, Johan WMVG, Luc B et al. “William Tell” Injury. MDCT of an arrow through the head. AJR 2004; 182:1551-3.
18. Krukemeyer MG, Grellner W, Gehlke G, Koops E, Puschel K. Survived crossbow injuries. Am J Forens Med Path 2006;3: 274-6.