

New Evidence of Prehistoric Arrow Wounds in the Iberian Peninsula

J. ARMENDARIZ,¹ S. IRIGARAI¹ AND F. ETXEBERRIA²

¹Centro de Estudios Tierra Estella, Apartado 17, Estella, Spain; and ²Departamento de Medicina Legal, Facultad de Medicina, Universidad del País Vasco, Apartado 1606, San Sebastian, Spain

ABSTRACT Recent excavations carried out in the Iberian Peninsula have revealed some skeletons with arrow wounds at sites dating from the neolithic to the Bronze Age. The discovery of burials in which the human remains have not been moved and the methodical nature of the excavation have made an *in situ* examination possible, and have confirmed this evidence as testimony of violent action, of which there are many other examples all over Europe. Four cases of silex arrowheads found in different human bones from the excavation of the hypogeum of Longar (Navarra, Spain), carried out between 1991 and 1993, are described.

Keywords: Palaeopathology, violence, injury, prehistory.

Introduction

The hypogeum of Longar is situated in the municipality of Viana (Navarra), in a mountainous area 750 m above sea-level, 13 km from the River Ebro. Nowadays this is an area of confluence between the autonomous territories of Navarra, La Rioja and the Basque Country, and since prehistoric times there has been continuous settlement due to the importance of the River Ebro, connecting the Mediterranean area of the Iberian Peninsula with the valleys of the Southern Pyrenean region (Figure 1).^{1,2}

Three seasons of excavation were carried out in the hypogeum of Longar in the years 1991, 1992 and 1993 and have identified a multiple burial structure of the megalithic type,³ different from the dolmen known until now in the middle basin of the River Ebro.

The burial chamber, 3.5 m long and 1.5 m wide, is roughly of horseshoe shape and was excavated in the bed rock and covered all along its perimeter by a wall of mortarless ashlar (Figure 2). The access to the chamber was through a door cut in a vertical slab, in the style of some monuments of chalcolithic chronology in the south of the Iberian Peninsula. The access corridor, almost entirely

disappeared today, and the covering system, consisting of two huge slabs horizontally placed over the opening to the chamber, have also been identified.

The falling in of this covering in prehistoric times allowed the burials to remain undisturbed until the present, and in its inner part the remains of about 112 individuals have been found, in the same state as the moment when the covering fell in, when the hypogeum must still have been in use. The absolute dating of this event is about 4450 BP, that is in the final neolithic-antique chalcolithic for this area of the peninsula.

Some of the individuals were complete, in the fetal position (Figure 3), some were really constrained, and of the remainder, who would have been deposited previously, there were the remains of bones in the anatomical position and piles of skulls in particular places in the chamber. Almost the only archaeological evidence was leaf-shaped silex arrowheads, four of which were found inside parts of the skeleton of four different individuals, all male; they are described in detail below. The arrowheads had either a fracture in the distal end or were only distal fragments.

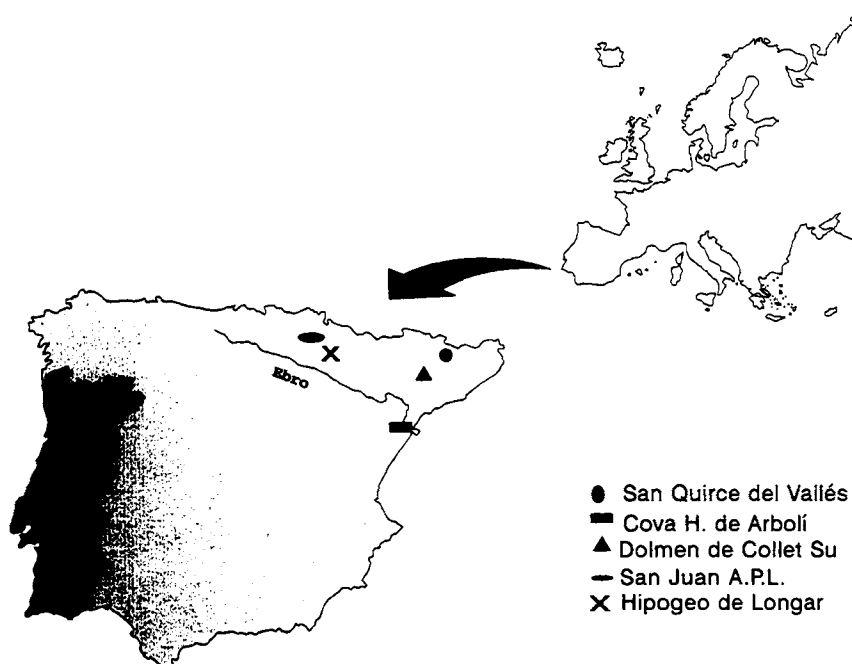


Figure 1. Position of the prehistoric sites in the Iberian Peninsula showing arrow wounds.



Figure 2. View of the hypogeum of Longar after excavation of the skeletal remains of more than 100 individuals.

Description of cases

Case 1

A young adult male. The arrowhead, 28 mm long and 13 mm wide, was found on the inner face

of the left 6th, 7th or 8th rib and over the costal canal. The head entered the rib tangentially and was held in place by new bone coming from the inner table of the rib (Figure 4). The outer side of the rib showed

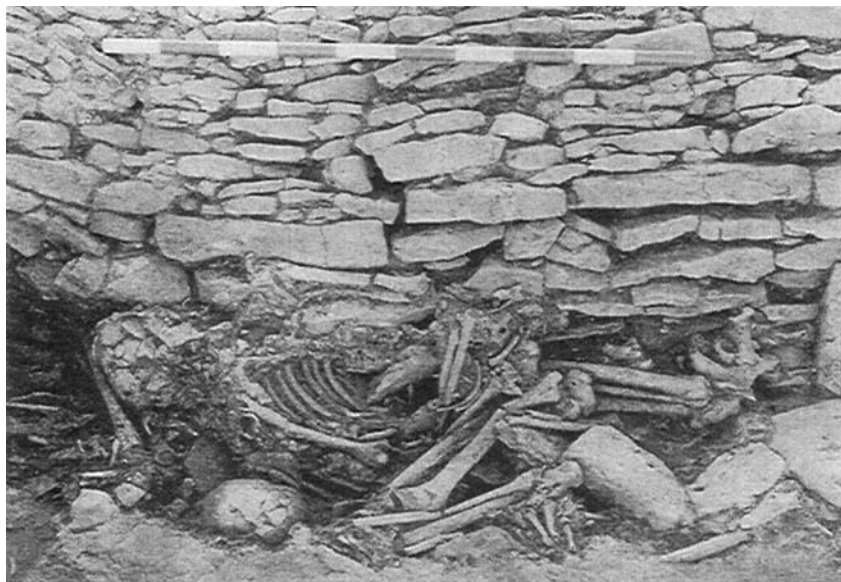

Figure 3. The anatomical relations remain despite the great fragmentation due to pressure.

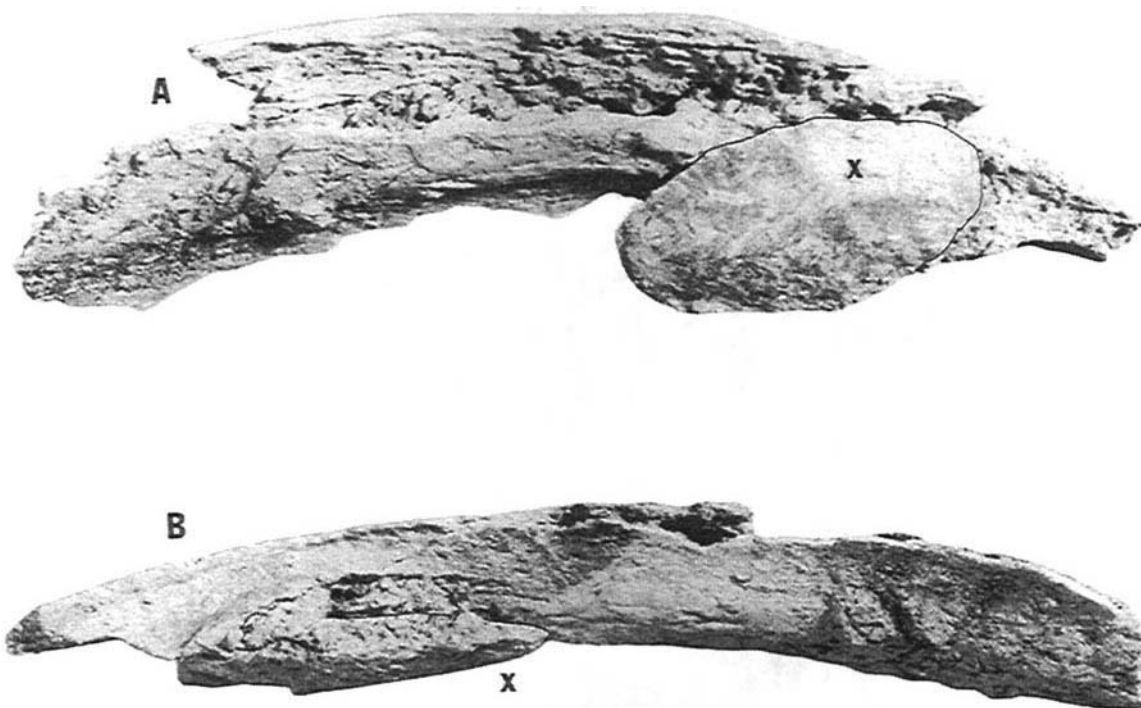


Figure 4. The silex arrowhead is held posteriorly by scar tissue on the inner face of the costal arch. Case 1 (A = interior aspect; B = inferior aspect; x = silex arrowhead).

signs of osteolysis and of post-mortem damage. To enter the thorax the arrow must have struck the left side of the chest (Figure 5), passing through the immediately superior intercostal

space passing very near the costal margin in an antero-posterior direction and slightly inferiorly, probably damaging the costal pleura and the lung (Figure 6).

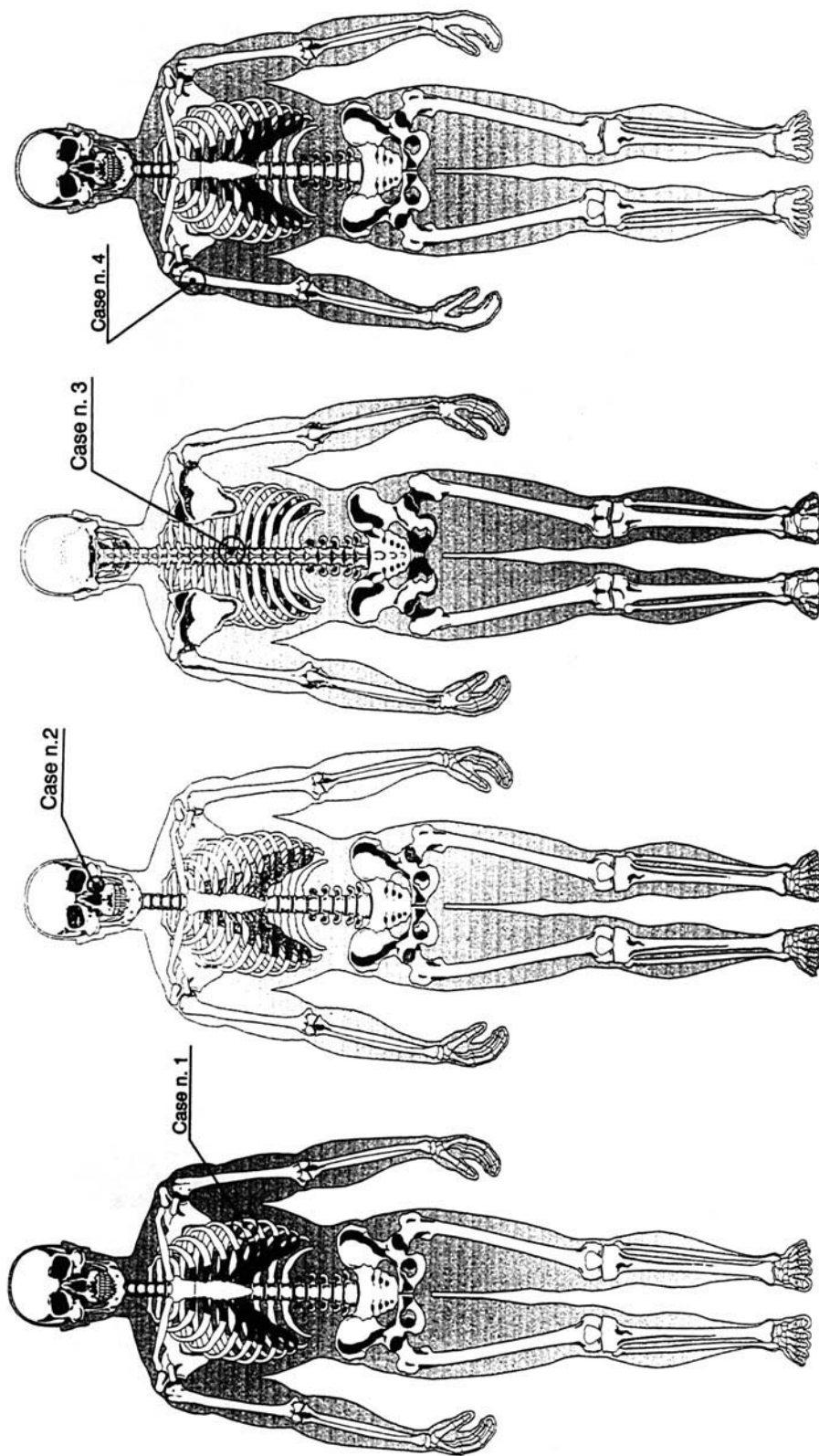


Figure 5. Schematic representation of the place of impact and penetration of the four arrows described in the hypogoeum of Longar.

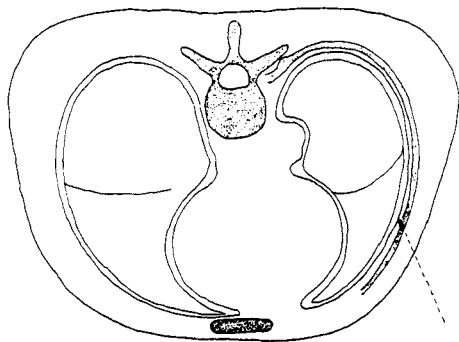


Figure 6. Cross-section of the trunk at the level of the thorax showing where the silex head of case 1 was placed.

Case 2

A young adult male. The arrowhead, 24 mm long and 10 mm wide, was in the left maxillary sinus and must have entered through the ipsilateral canine fossa in which an irregular perforation of 9 mm maximum diameter was found (Figure 7). There are some signs of impact in the wall of the canine fossa where the arrow struck after passing through the soft tissues of the face (Figures 5 and 8). There were no signs of healing in the bone although the wound itself would not have caused the death of this individual.

This case is similar to one published by Sciulli *et al.*⁴ in a native American. In this case a silex arrowhead had entered the maxillary sinus at the rear of the zygomatic apophysis of the maxilla. There were some signs of healing and resorption of bone in the anterior wall of the sinus, corresponding to the canine fossa, as a consequence of contact with the arrowhead in this region.

Case 3

The arrowhead, 40 mm long and 15 mm wide, was in the vertebral canal of the 5th, 6th or 7th thoracic vertebra (Figure 9). The arrowhead was broken and had entered through the right lamina from right to left and slightly upward. It struck in the middle of the back (Figure 5) and would have cut the spinal cord. There are no signs of healing in the bone and this would have resulted in the death of the individual after immediate paralysis due to the sectioning of the cord. There was a distal fracture in the arrowhead which was produced at the moment of impact or in the

attempt to remove the arrow, or during the time when the body was moved; a similar finding has been described by Reyher.⁵

The site of the arrow in the vertebral body is similar to that described in San Juan ante Portam Latinam, although there some signs of healing were found because the arrow did not enter the vertebral canal but had stopped in the lamina without causing the death of that individual.⁶ There is a further case referring to a lumbar vertebra from a site in Illinois in which the arrowhead was found in the vertebral body having entered from the rear and crossed the vertebral canal.⁷

There was another broken arrowhead in the thorax of this individual and we think that it was inserted inside the body after death.

Case 4

A mature adult male with signs of arthrosis in the vertebral column. The arrowhead, 25 mm long and 10 mm wide, was in the superior portion of the right humerus having broken due to bending after impact. It had entered perpendicularly to the diaphysis in the antero-lateral face of the humerus at the rear of the bicipital groove 20 mm below the greater tuberosity (Figures 11 and 12). Having struck the right shoulder (Figure 5) the arrow would have passed through the deltoid muscle in an antero-posterior direction, slightly upwards and with minimal lateral deviation. There are no signs of healing in the bone even though this wound would not have resulted in the death of the individual.

This case is similar to one described by Reyher⁵ in the chalcolithic cave of Lave (Saint Saturnin d'Apt-Vaucluse, France), although in Reyher's case there were signs of healing. At the same site there were two more examples of arrowheads embedded perpendicularly in the femoral shaft of two individuals; in both cases the arrowheads were broken.

Discussion and conclusions

Four sites (Figure 1) have been identified previously in the Iberian Peninsula with reliable evidence of wounds made by arrowheads and with

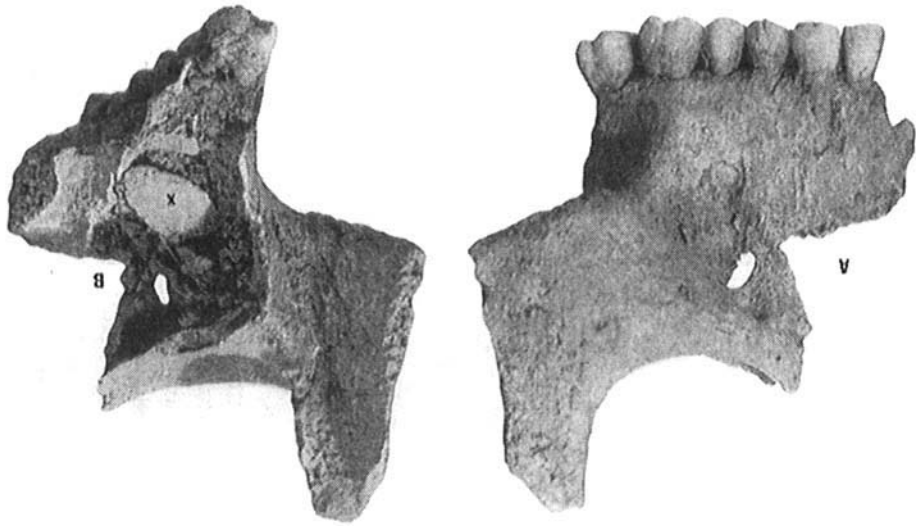


Figure 7. The arrowhead is placed in the left maxillary sinus and has entered through the fossa carina or anterior wall. Case 2 (A = anterior aspect; B = posterior aspect; x = silex arrowhead).

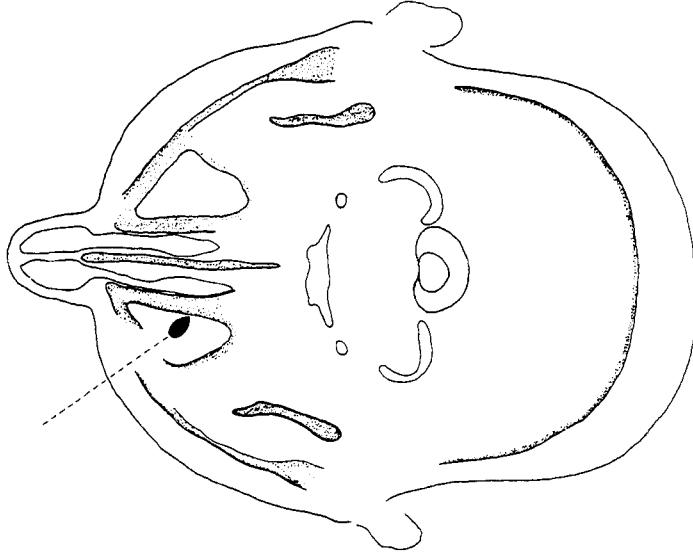

Figure 8. Cross-section of the head at the level of the maxillary sinuses in order to show the place where the silex head was placed and the direction of penetration in case 2.

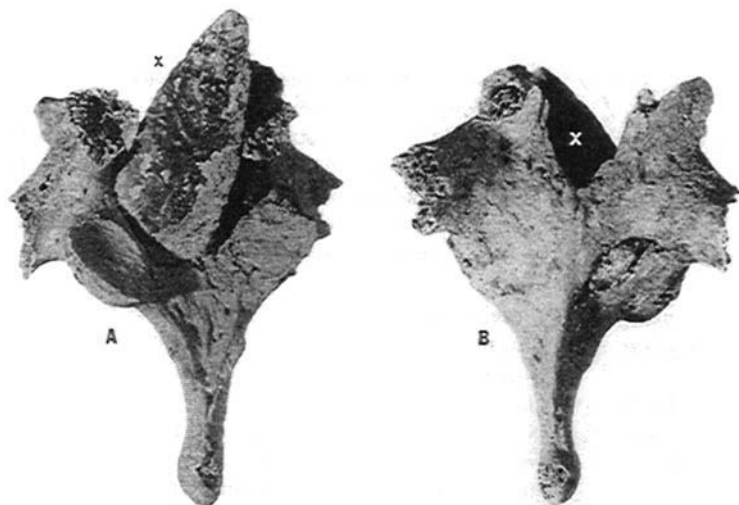


Figure 9. In this case, the head would have entered through the vertebral arch crossing the vertebral duct cutting the spine. Case 3 (A = anterior aspect; B = posterior aspect; x = silex arrowhead).

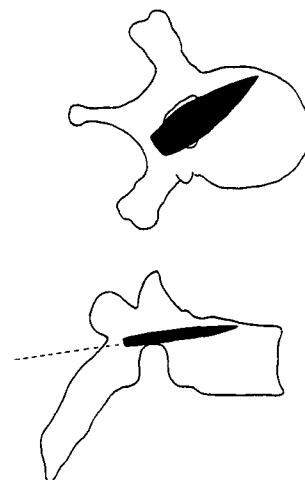


Figure 10. Schematic representation of the place where the silex head in case 3 is placed.

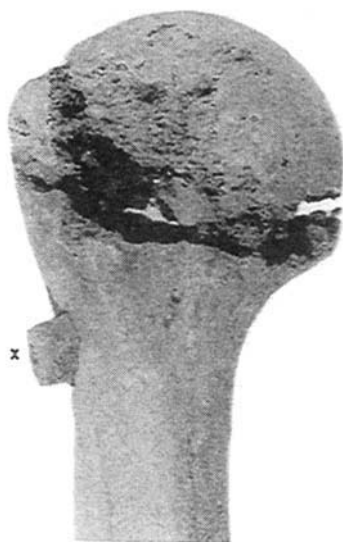

Figure 11. The silex head enters the diaphysis of the humerus perpendicularly and is broken posteriorly. Case 4 (x = silex arrowhead).



Figure 12. Schematic representation of the place where the arrowhead in case 4 is placed in the humerus.

a prehistoric chronology: the dolmen of Collet Su;⁸ Cova H. De Arboli;⁸ San Juan ante Portem Latinam with nine cases;⁹ and San Quirce del Valles.¹⁰ Others have been mentioned but cannot be confirmed or verified from the palaeopathological point of view.

San Juan ante Portem Latinam has most in common with the hypogeum of Longar due to its geographical proximity (about 20 km), the number

of injured individuals and the chronological coincidence. At both sites there are wounds with signs of healing corresponding to injuries that happened some time before death and others are characterized by a lack of healing corresponding to events that caused the violent death of the individuals. We hope that further studies in this area will throw further light on the origin of these wounds.¹¹

References

1. Andres, T. Ritos funerarios de la Cuenca Media del Ebro: Neolítico y Eneolítico. *Berceo*, 1979; 97: 3-25.
2. Andres, T. Sepulturas calcolíticas de inhumación múltiple simultánea en la Cuenca Media del Ebro. *Caesaraugusta*, 1990; 66-67: 13-28.
3. Armendariz, J. and Irigaray, S. Nuevo monumento de puerta perforada en Navarra. *Zephyrus*, 1991-1992; 24-25: 517-520.
4. Sciulli, P. W., Pacheco, P. J. and Wymer, D. A. Traumatic pathology in a late prehistoric individual from central Ohio. *Journal of Paleopathology*, 1989; 2: 3-8.
5. Reyher, M. A. Contribution à l'Etude de la Paléopathologie osseuse en Provence et Bas-Languedoc. PhD thesis, Faculté Mixte de Médecine et de Pharmacie de Marseille, 1961.
6. Etxeberria, F., Herrasti, L. and Vegas, J. I. Arrow wounds during Prehistory in the Iberian Peninsula with regard to San Juan ante Portam Latinam. *IX European Meeting of the Paleopathology Association, Barcelona, 1992*, in press.
7. Ortner, D. J. and Putschar, W. G. J. Identification of Pathological Conditions In Human Skeletal Remains. Washington: Smithsonian Institution, 1985.
8. Campillo, D. Paleopatología del cráneo en Cataluña, Levante y Baleares. Barcelona: Montblanc-Martín, 1977.
9. Etxeberria, F. and Vegas, J. I. Heridas por flecha durante la Prehistoria en la Península Ibérica. *Munibe (Antropología-Arkeología)*, 1992; suplemento 8: 129-136.
10. Campillo, D., Mercadal, O. and Blanch, R. M. A mortal wound caused by a flint arrowhead in individual MF-18 of the neolithic period exhumed at Sant Quirze del Valles. *International Journal of Osteoarchaeology*, 1993; 3: 145-150.
11. Etxeberria, F. and Vegas, J. I. Agresividad social o guerra? durante el Neo-eneolítico en la cuenca media del Valle del Ebro, a propósito de San Juan ante Portam Latinam (Rioja Alavesa). *Munibe (Antropología-Arkeología)*, 1988; suplemento 6: 105-112.