International Journal of Paleopathology 9 (2015) 76–81

Contents lists available at ScienceDirect

International Journal of Paleopathology

journal homepage: www.elsevier.com/locate/ijpp

Case Study

Flint arrowhead embedded in a human humerus from the Bronze Age site in the Tollense valley, Germany – A high-resolution micro-CT study to distinguish antemortem from perimortem projectile trauma to bone

Stefan Flohr[a,b,*], Ute Brinker[c], Annemarie Schramm[c], Uwe Kierdorf[a], Andreas Staude[d], Jürgen Piek[e], Detlef Jantzen[c], Karlheinz Hauenstein[f], Jörg Orschiedt[g]

[a] Department of Biology, University of Hildesheim, Universitätsplatz 1, 31141 Hildesheim, Germany
[b] Thuringian State Office for the Preservation of Historical Monuments and Archaeology, Humboldtstraße 11, 99423 Weimar, Germany
[c] State Authority for Culture and Preservation of Monuments, Mecklenburg-Western Pomerania, Domhof 4/5, 19055 Schwerin, Germany
[d] BAM Federal Institute for Materials Research and Testing, Division 8.5 "Micro NDE", Unter den Eichen 87, 12205 Berlin, Germany
[e] Klinik für Neurochirurgie, Universitätsmedizin Rostock, Schillingallee 35, 18057 Rostock, Germany
[f] Institut für Diagnostische und Interventionelle Radiologie, Universitätsmedizin Rostock, Schillingallee 35, 18057 Rostock, Germany
[g] Department of History and Cultural Studies, Institute of Prehistoric Archaeology, University of Berlin, Altensteinstraße 15, 14195 Berlin, Germany

ARTICLE INFO

Article history:
Received 5 September 2014
Received in revised form 18 February 2015
Accepted 18 February 2015

Keywords:
Arrow wound
Differential diagnosis
Prehistoric warfare
Antemortem and perimortem lesions
Trauma

ABSTRACT

The Bronze Age site in the Tollense valley, Germany, has yielded thousands of human and animal bones and a number of archaeological artifacts. Several of the human bones exhibit blunt and sharp force lesions, and the assemblage has been interpreted as representing victims of a large scale conflict. One of the earliest finds is a human humerus with an embedded flint arrowhead. Alleged signs of healing initially reported for this humerus based on clinical CT imaging were interpreted as evidence of an antemortem lesion. The present study, using micro-CT imaging, revealed that the arrowhead lesion in the humerus, contrary to the previous interpretation, shows no signs of healing. The structure previously assumed to represent a sclerotic margin around the wound canal was shown to actually represent compacted trabecular debris. Thus, our re-analysis of the specimen led to a re-classification of the arrow wound as a perimortem lesion. The findings of the present study demonstrate the value of micro-CT imaging as a non-destructive method for obtaining information on the nature of bone lesions and healing reactions critical for the reconstruction of interpersonal conflict scenarios in the past.

© 2015 Elsevier Inc. All rights reserved.

1. Introduction

The value of radiological techniques for studying human remains, including dry bones and mummies, has repeatedly been stressed (Chhem and Brothwell, 2008; Chhem and Rühli, 2004; Ryan and Milner, 2006). One of the major advantages of these techniques is their non-destructive nature. From a methodological point of view, radiological techniques have a major role in paleopathological studies, not only because they provide important diagnostic features that cannot be detected by external inspection but also since they connect clinical and bioarchaeological studies by shared diagnostic criteria (Mays, 2008). However, some differences between clinical and bioarchaeological diagnostic procedures exist due to the fact that clinicians usually deal with living patients, while bioarchaeologists study human remains that may have been altered by taphonomic processes. This aspect is of particular importance since the results of these processes can mimic pathological conditions (Buikstra, 2010; Ortner, 2003). For example, invaded soil particles in dry bones might be confused with neoplastic bone tissue or osseous callus in radiographic images (Mays, 2008).

While conventional CT scanning utilizing clinical equipment has become a widely used tool in the analysis of archaeological bones, micro-CT imaging is still rarely employed due to the scarcity of the equipment (Ryan and Milner, 2006). This technique provides a much higher resolution than clinical CT imaging, which may be of crucial importance for a correct diagnosis of changes seen in archaeological bone.

* Corresponding author at: Department of Biology, University of Hildesheim, Universitätsplatz 1, 31141 Hildesheim, Germany. Tel.: +49 512188340720.
E-mail address: flohrs@uni-hildesheim.de (S. Flohr).

http://dx.doi.org/10.1016/j.ijpp.2015.02.004
1879-9817/© 2015 Elsevier Inc. All rights reserved.

Fig. 1. Location of the Bronze Age site in the Tollense valley in Mecklenburg-Western Pomerania (Germany).

Determining the temporal relationship between the damage to a bone and the death of an individual is a significant question for both bioarchaeology and forensic archaeology (De Boer et al., 2015; Quatrehomme and İşcan, 1997; Rodríguez-Martín, 2006; Walker, 2001). The term antemortem trauma refers to trauma occurring some time before death, such that signs of healing can be seen. Postmortem damage refers to changes occurring after the death of an individual due to taphonomic processes. If the post-traumatic interval, i.e., the time between the trauma and the death of an individual, is too short for the development of signs of healing, or if a fresh bone is damaged shortly after death, a defect cannot reliably be determined as being antemortem or postmortem. Defects formed during this time span are referred to as perimortem. The time elapsing between an injury to bone and the occurrence of first signs of healing depends on various factors such as type and severity of the injury, and age and health status of the individual (Byers, 2008). In addition, the ability to distinguish antemortem bone lesions, showing signs of healing from perimortem lesions, lacking such signs, depends on the diagnostic techniques applied in the analysis. The present study demonstrates how micro-CT imaging can be used for distinguishing between antemortem and perimortem projectile trauma to bone. The case described is a human humerus with an embedded flint arrowhead from the Bronze Age site in the Tollense valley in Germany.

2. The Bronze Age site in the Tollense valley, Germany

During the last two decades, more than 9000 human skeletal remains and more than 3000 animal bones have been recovered over about two kilometers along the small river Tollense in the federal state of Mecklenburg-Western Pomerania, Germany (Fig. 1). On the basis of these finds, the minimum number of human individuals represented at the site is calculated at 124. The finds were obtained during excavations in the close vicinity of the riverside, during diving surveys in the river, and from material dredged from the riverbed (Jantzen et al., 2008, 2011). Archaeologically, a couple of single "spots" along the river were defined for practical reasons since it is not possible to excavate the entire area. However, it is currently assumed that the spots over the entire length represent a single site, originating from a common event (Brinker et al., 2013). Conventional and AMS radiocarbon dating of a number of human and animal bones date the site to about 1200 cal BCE (range 1080 ± 60 to 1370 ± 40; for details see Jantzen et al., 2011). Archaeological dating of artifacts including arrowheads made from flint and bronze confirm the radiocarbon dating and place the site in Period III of the Nordic Bronze Age (Jantzen et al., 2008, 2011). One focus of the ongoing excavations was the site ("spot") Weltzin 20. Here alone, about 7500 human bones were recovered by the end of 2013.

The majority of bones, not only at Weltzin 20, but throughout the site, have been found commingled, with anatomically joining elements being rare. Demographic analyses of the current data, based on isolated skulls, pelves, and femora, suggest that the majority of individuals were young adult males with very few females present (Brinker et al., 2013; Flohr et al., 2014). Several bones exhibit signs of blunt and sharp force trauma (Brinker et al., 2013). A preliminary interpretation suggests that following a large-scale battle, numerous corpses were thrown into the river and underwent decomposition. The osseous remains became scattered depending on their specific fluvial transportation properties. A number of questions regarding the site are still unanswered, including where the corpses were thrown into the river. It is also unknown whether all victims were killed in action or whether some of them represent sacrificed prisoners. Some of the traumatic lesions were reported to show signs of healing, thereby indicating that they had been survived for some time. Among these bones is a human humerus exhibiting an arrow wound showing alleged signs of initial healing (Brinker, 2009). This specimen was submitted to a critical re-evaluation using high-resolution micro-CT imaging. This led to a rejection of the original interpretation of the lesion as being antemortem and its reclassification as a perimortem lesion.

Fig. 2. Human right humerus (find number ALM1996/0277-0001-1) with embedded flint arrowhead, posterior view. Bar indicates 1 cm.

3. Materials and methods

3.1. The humerus

The initial finds in the Tollense valley lacked an archaeological context, and for a number of years received no further attention. This changed dramatically in 1996 when the amateur archaeologist Roland Borgwardt found an intact human right humerus (find number ALM1996/0277-0001-1) with a flint arrowhead embedded in the bone (Fig. 2). This find proved the antiquity of the humerus and (by inference) also of the other bones recovered from the Tollense valley, and it was the starting point of systematic archaeological investigations by the State Authority for Culture and Preservation of Monuments of the federal state of Mecklenburg-Western Pomerania, Germany.

Following recovery, the humerus was gently cleaned under running tap water and air dried. It is very well preserved, with no breakage and almost no cortical erosion. The dimensions of the humerus (maximum length 340 mm; transverse head diameter 44.2 mm; vertical head diameter 48.0 mm) suggest that it belonged to a male individual (Dittrick and Myers Suchey, 1986). The epiphyses are fused, and only minor degenerative changes are present on the articular surfaces, at the articular rims and at attachment sites. This suggests that the humerus belonged to a young adult to middle adult (20–50 years) individual.

Proximally, a flint arrowhead (length 36.5 mm) was embedded in the area of the greater tubercle. The projectile had penetrated the bone in the attachment facet of the teres minor muscle in an approximately 45° angle relative to the shaft axis. The bifacially worked projectile, which possesses a concave base (Fig. 3), was embedded in the humerus for approximately half its length (Fig. 4). The arrowhead is complete, i.e., it did not break upon impact, probably due to the relatively thin layer of cortical bone at the entry site compared to the humeral shaft.

As in many other bones from the Tollense valley, clinical CT scanning was routinely performed on this humerus in order to obtain further information concerning the injury. The clinical CT image shows a narrow radiodense rim adjacent to the projectile (Fig. 4). This radiodense rim was originally interpreted as a sclerotic margin suggesting healing and interpreted as evidence that the lesion was survived for at least some weeks (Brinker, 2009). Consequently, the case was diagnosed as representing an antemortem projectile trauma.

3.2. Methods

Micro-CT imaging was performed on the BAM 225 kV-microCT-device. This device features an X-RAY WorX micro-focus X-ray tube with 225 kV maximum acceleration voltage and a minimum focal spot size of approximately 5 μm. The detector is a flat-panel (PerkinElmer) with 2048 × 2048 pixels at a pitch of 0.2 mm. For the measurement of the humerus, an acceleration voltage of 100 kV, a current of 380 μA, and a pre-filter of 0.5 mm copper were used. 1200 projection images with 4 s exposure time each were taken for



Fig. 3. 3D-micro-CT reconstruction of the flint arrowhead.

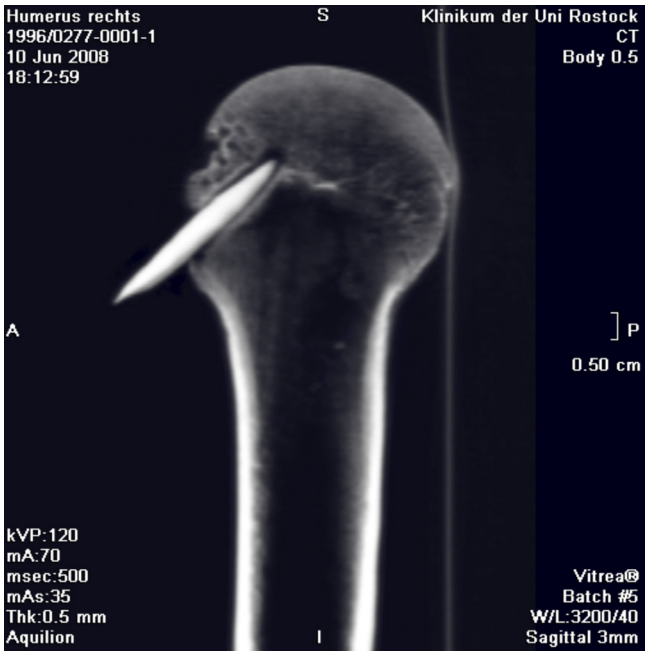

Fig. 4. Clinical CT image of the proximal humerus with embedded flint arrowhead. Note radiodense lining of the wound canal.

the full rotation. The reconstruction of the volume data was performed with a standard FDK algorithm. The resulting voxel size of the volume data is 55 μm^3.

During drying of the bone, the arrow head became loosened and was removed prior to the study. In order to avoid damage inside the wound canal, the projectile was not reinserted into the bone. Therefore, the humerus and the projectile were scanned separately.

4. Results

The bone surface surrounding the entry site of the projectile was slightly eroded postmortem and thus provides no clues for judging whether or not the injury was survived. However, osseous callus or larger areas or reactive bone formation are missing.

The penetrating canal shows a rhomboid shape corresponding to that of the arrowhead (Fig. 5). Further inside the bone, the shape of the canal becomes less distinct due to the lack of a clear border. This is due to the loose trabecular structure in the center of the humeral head compared to the denser peripheral zone. Conforming to the shape of the projectile, the wound canal tapers toward its end. A thin layer of a homogenous material, with a lower radiodensity than the bone, lines parts of the wound canal except for its innermost portion (Fig. 6). This material most likely represents infiltrated fine-grained sedimentary material that filled the small gap between the projectile and the wall of the wound canal. The presence of a gap between the projectile and the surrounding bone could result from (a) a rotational movement of the penetrating arrowhead, (b) a rotational component during an attempt to remove the arrow (Gaudio et al., 2014), or (c), more likely, a slight shrinking of the bone in the course of diagenesis and drying (Bertrand and Oxenham, in press; Piepenbrink, 1986).

The trabecular bone tissue in the path of the penetrating projectile became crushed and the trabecular debris was displaced laterally. This led to the formation of a rim of compacted trabecular debris along the wound canal (Figs. 5 and 6). This rim appears as a rather homogenous radiodense line in the clinical CT image (Fig. 4). However, both the single micro-CT slices as well as the 3D-rendered view of the micro-CT image (Fig. 7) show that the radiodense appearance of the rim is not indicative of a post-traumatic bone

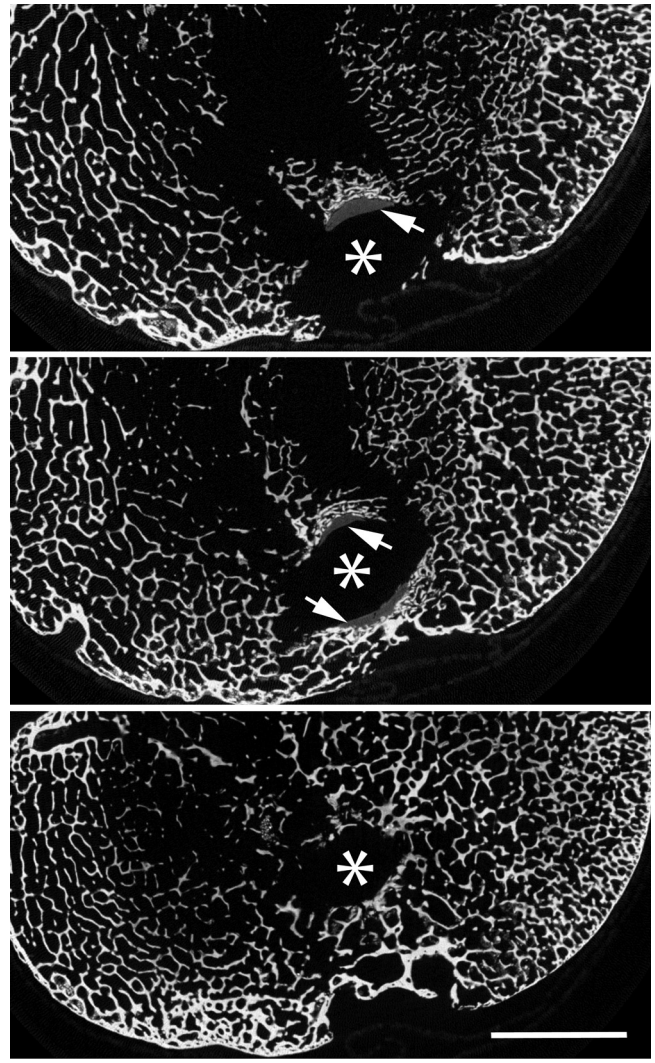

Fig. 5. Micro-CT coronal section images of the proximal humerus showing the wound canal (asterisks) and infiltrated sediment (arrows). Bar indicates 1 cm.

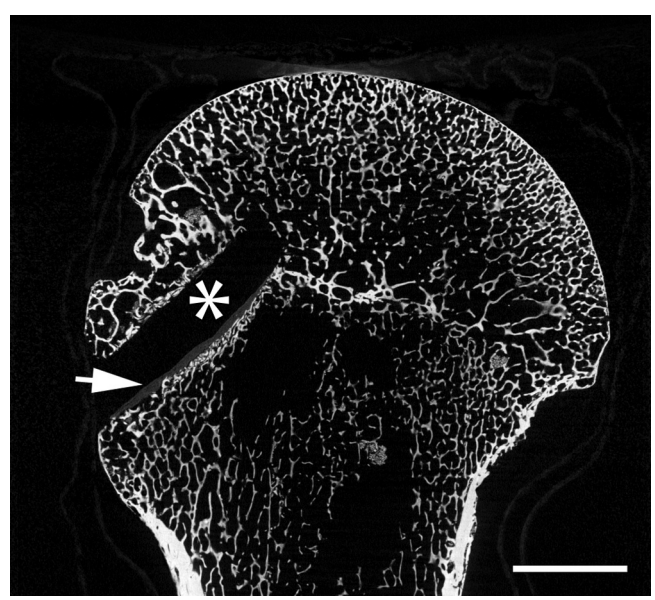

Fig. 6. Micro-CT frontal section image of the proximal humerus showing the wound canal (asterisk) and infiltrated sediment (arrow). Bar indicates 1 cm.

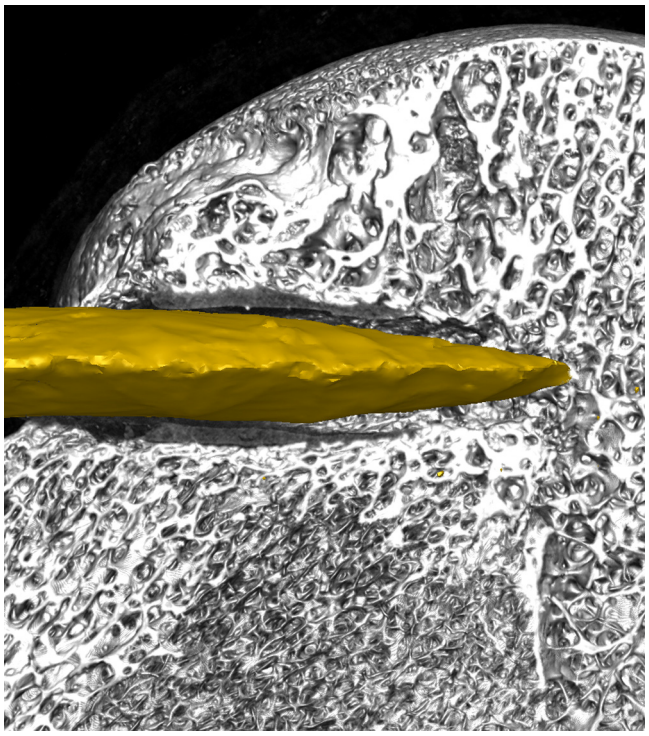

Fig. 7. 3D-reconstruction of the proximal humerus and the flint arrowhead.

reaction leading to the formation of a sclerotic margin, but due to the local accumulation of trabecular debris. This is consistent with the arrow wound being of a perimortem nature and does not support the earlier notion that it constitutes an antemortem lesion.

5. Discussion

Both in paleopathology and forensics, the distinction between antemortem and perimortem conditions is often crucial to the interpretation of a case (Byers, 2008; Ubelaker and Montaperto, 2013). Evidence of bone healing is the decisive indicator that a lesion was survived for a period of time, and thus constitutes an antemortem injury. Reactions in the form of bone resorptive and/or formative activities can first be detected radiologically and later by gross morphological examination in macerated (archaeological) bones only some time after the onset of the healing process.

Signs of wound healing detectable by radiographic examination of dry bones include the presence of sclerotic lesion margins. According to De Boer et al. (2015), the sclerosis becomes visible 12–20 days after the trauma. This would support the interpretation by Brinker (2009) of an antemortem nature of the arrow wound in the humerus from the Tollense valley, if the radiodense rim around the wound canal seen in this specimen actually was a sclerotic margin. Micro-CT imaging in this study, however, indicates that the radiodense rim along the wound canal is composed of compacted trabecular debris and does not represent a sclerotic margin. This means that contrary to the earlier interpretation, there is no evidence of a proliferative reaction in the humerus. The findings of the present study therefore suggest that the arrow lesion to the humerus occurred perimortem.

Several other cases of arrow wounds are known from archaeological contexts (Armendariz et al., 1994; Campillo et al., 1993; Lieverse et al., 2014; Milner, 2005; Polet et al., 1996; Ryan and Milner, 2006; Sciulli et al., 1988; Silva and Marques, 2010). For instance, an embedded stone arrowhead fragment was found in the tibia of a female from Norris Farms, Illinois, dating to about 1300 CE (Ryan and Milner, 2006). The surface around the entry site shows clear signs of bone remodeling, and micro-CT imaging revealed that the wound canal is lined by a distinct layer of newly formed bone. These features are thus indicative of an antemortem trauma.

Arrow wounds may be fatal if vital organs are injured. This was assumed to be the case for an arrow wound in the second cervical vertebra found in an individual from the Neolithic of Portugal (Silva and Marques, 2010). Here, the projectile likely produced severe damage to the spinal cord. In another Neolithic case (from Spain), an arrow was assumed to have perforated the aorta thus causing a fatal injury (Campillo et al., 1993). Anatomically, the injury seen in the humerus from the Tollense valley was most likely not fatal since neither larger vessels nor any vital organs are present in this area. The cause of death of the individual therefore remains unknown. Multiple arrows hitting the individual, with one or more of the arrows injuring large blood vessels or vital organs, is a possible scenario, but so too is death from septicemia occurring a couple of days after a solitary injury. However, in the latter case, one would expect that the projectile had been removed. Therefore, death on the assumed battlefield around the time of the injury to the humerus seems more likely.

The alleged signs of healing in the humerus from the Tollense valley have been used as confirming evidence to support the view that the conflict in the Tollense valley extended over a longer period of time and involved several battles (Brinker, 2009; Jantzen et al., 2011). This interpretation is no longer substantiated based on the result of our re-analysis of the specimen. The results of the present study caution against interpretations in bioarchaeology that are not based on clearly defined and sufficiently detailed diagnostic criteria. Specifically, our findings caution against considering any radiodense structure visible in a radiograph as being indicative of a bone reaction leading to sclerosis, since other processes can also lead to a local increase in the radiodensity of bone (Mays, 2008).

In conclusion, our re-analysis of the human humerus with an embedded flint arrowhead from the Tollense valley led to a re-classification of the arrow wound as a perimortem lesion. This illustrates that in “forensic bioarchaeology” (Martin and Anderson, 2014) advanced techniques like micro-CT imaging are often required to obtain a reliable diagnosis.

References

Armendariz, J., Irigari, S., Etxeberria, F., 1994. New evidence of prehistoric arrow wounds in the Iberian peninsula. Int. J. Osteoarchaeol. 4, 215–222.

Bertrand, J., Oxenham, M.F., 2015. Low-temperature-induced bone shrinking: a controlled study using kangaroo femora. Austral. J. For. Sci. (in press).

Brinker, U., (Master thesis) 2009. Das Tollensetal zwischen Wodarg und Weltzin, Lkr. Demmin. Schauplatz einer kriegerischen Auseinandersetzung in der Älteren Bronzezeit? Eine osteoarchäologische Analyse. University of Hamburg.

Brinker, U., Flohr, S., Piek, J., Orschiedt, J., 2013. Human remains from a Bronze Age site in the Tollense Valley: victims of a battle? In: Knüsel, C., Smith, M.J. (Eds.), The Routledge Handbook of the Bioarchaeology of Human Conflict. Routledge Ltd., Andover, pp. 146–160.

Buikstra, J.E., 2010. Paleopathology: a contemporary perspective. In: Larsen, C.S. (Ed.), A Companion to Biological Anthropology. Blackwell Companions to Anthropology, vol. 7. Wiley-Blackwell, Chichester, U.K./Malden, MA, pp. 395–411.

Byers, S.N., 2008. Introduction to Forensic Anthropology, 3rd ed. Allyn & Bacon, Boston.

Campillo, D., Mercadal, O., Blanch, R.-M., 1993. A mortal wound caused by a flint arrowhead in individual MF-18 of the Neolithic period exhumed at Sant Quirze des Valles. Int. J. Osteoarchaeol. 3, 145–150.

Chhem, R., Brothwell, D.R. (Eds.), 2008. Paleoradiology: Imaging Mummies and Fossils. Springer, Berlin/New York.

Chhem, R.K., Rühli, F.J., 2004. Paleoradiology: current status and future challenges. Can. Assoc. Radiol. J. 55, 198–199.

De Boer, H.H., van der Merwe, A.E., Hammer, S., Steyn, M., Maat, G.J.R., 2015. Assessing posttraumatic time interval in human dry bone. Int. J. Osteoarchaeol. 25, 98–109.

Dittrick, J., Myers Suchey, J., 1986. Sex determination of prehistoric central California skeletal remains using discriminant analysis of the femur and humerus. Am. J. Phys. Anthropol. 70, 3–9.

Flohr, S., Brinker, U., Spanagel, E., Schramm, A., Orschiedt, J., Kierdorf, U., 2014. Killed in action? A biometrical analysis of femora of supposed battle victims from the Middle Bronze Age site of Weltzin 20, Germany. In: Martin, D.L., Anderson, C.P. (Eds.), Bioarchaeological and Forensic Perspectives on Violence. How Violent Death is Interpreted from Skeletal Remains. Cambridge University Press, Cambridge, pp. 17–33.

Gaudio, D., Giancamillo, M., Gibelli, D., Galassi, A., Cerutti, E., Cattaneo, C., 2014. Does cone beam CT actually ameliorate stab wound analysis in bone? Int. J. Legal Med. 128, 151–159.

Jantzen, C., Jantzen, D., Terberger, T., 2008. Der Fundplatz Weltzin, Lkr. Demmin – ein Zeugnis bronzezeitlicher Konflikte? In: Pieck, J., Terberger, T. (Eds.), Traumatologische und pathologische Veränderungen an prähistorischen und historischen Skelettresten-Diagnose, Ursachen und Kontext. Interdisziplinärer Workshop in Rostock-Warnemünde, 17–18. November 2006. Archäologie und Geschichte im Ostseeraum Archaeology and history of the Baltic 3. VML – Verlag M. Leidorf, Rahden, pp. 89–97.

Jantzen, D., Brinker, U., Orschiedt, J., Heinemeier, J., Piek, J., Hauenstein, K., Krüger, J., Lidke, G., Lübke, H., Lampe, R., Lorenz, S., Schult, M., Terberger, T., 2011. A Bronze Age battlefield? Weapons and trauma in the Tollense Valley, north-eastern Germany. Antiquity 85, 417–433.

Lieverse, A.R., Pratt, I.V., Schulting, R.J., Cooper, D., Bazaliiskii, V.I., Weber, A.W., 2014. Point taken: an unusual case of incisor agenesis and mandibular trauma in Early Bronze Age Siberia. Int. J. Paleopathol. 6, 53–59.

Martin, D.L., Anderson, C.P., 2014. Introduction: interpreting violence in the ancient and modern world when skeletonized bodies are all you have. In: Martin, D.L., Anderson, C.P. (Eds.), Bioarchaeological and Forensic Perspectives on Violence. How Violent Death is Interpreted from Skeletal Remains. Cambridge University Press, Cambridge, pp. 3–13.

Mays, S., 2008. Radiography and allied techniques in the palaeopathology of skeletal remains. In: Pinhasi, R., Mays, S. (Eds.), Advances in Human Palaeopathology. John Wiley & Sons, Chichester, England/Hoboken, NJ, pp. 77–100.

Milner, G.R., 2005. Nineteenth-century arrow wounds and perceptions of prehistoric warfare. Am. Antiquity 70, 144–156.

Ortner, D.J., 2003. Trauma. In: Ortner, D.J. (Ed.), Identification of Pathological Conditions in Human Skeletal Remains. , 2nd ed. Academic, Amsterdam/London, pp. 119–177.

Piepenbrink, H., 1986. Two examples of biogenous dead bone decomposition and their consequences for taphonomic interpretation. J. Archaeol. Sci. 13, 417–430.

Polet, C., Dutour, O., Orban, R., Jadin, I., Louryan, S., 1996. A healed wound caused by a flint arrowhead in a Neolithic human Innominate from the Trou Rosette (Furfooz, Belgium). Int. J. Osteoarchaeol. 6, 414–420.

Quatrehomme, G., İşcan, M.Y., 1997. Postmortem skeletal lesions. For. Sci. Int. 89, 155–165.

Rodríguez-Martín, C., 2006. Identification and differential diagnosis of traumatic lesions of the skeleton. In: Schmitt, A., Cunha, E., Pinheiro, J. (Eds.), Forensic Anthropology and Medicine: Complementary Sciences from Recovery to Cause of Death. Humana Press Inc., Totowa, NJ, pp. 197–221.

Ryan, T.M., Milner, G.R., 2006. Osteological applications of high-resolution computed tomography: a prehistoric arrow injury. J. Archaeol. Sci. 33, 871–879.

Sciulli, P.W., Pacheco, P.J., Wymer, D.A., 1988. Traumatic pathology in a late pre historic individual from central Ohio. J. Paleopathol. 2, 3–8.

Silva, A.M., Marques, R., 2010. An arrowhead injury in a Neolithic human axis from the natural cave of Lapa do Bugio (Sesimbra, Portugal). Anthrop. Sci. 118, 185–189.

Ubelaker, D., Montaperto, K.M., 2013. Trauma interpretation in the context of biological anthropology. In: Knüsel, C., Smith, M.J. (Eds.), The Routledge Handbook of the Bioarchaeology of Human Conflict. Routledge Ltd., Andover, pp. 25–38.

Walker, P.L., 2001. A bioarchaeological perspective on the history of violence. Ann. Rev. Anthropol. 30, 573–596.